Evidence-Based Medicine: Cutaneous Facial Malignancies: Nonmelanoma Skin Cancer

Karen L. Connolly, M.D.
Kishwer S. Nehal, M.D.
Joseph J. Disa, M.D.

New York, N.Y.

Learning Objectives: After studying this article, the participant should be able to: 1. Identify clinical features of nonmelanoma skin cancer; 2. Distinguish low-risk versus high-risk basal cell carcinoma and squamous cell carcinoma; 3. Define appropriate management based on current guidelines for various types of basal cell and squamous cell carcinoma.

Summary: Skin malignancies are the most prevalent cancers, and plastic surgeons are often the primary physicians engaged in diagnosis and management of these lesions. Proper management includes distinguishing between high-risk and low-risk lesions and determining treatment accordingly. The aim of this Continuing Medical Education article is to review the diagnosis and management of common and uncommon facial skin malignancies, including basal cell carcinoma, squamous cell carcinoma, actinic keratosis, keratoacanthoma, Merkel cell carcinoma, atypical fibroxanthoma, sebaceous carcinoma, and microcystic adnexal carcinoma. (*Plast. Reconstr. Surg.* 139: 181e, 2017.)

Downloaded from http://journals.lww.com/plasreconsurg by RzUSysRlyqiZg+J5ivYjoyV6s6t/G+nVOYytTyC2t5u bv2Mw44Nk6awDKbkjm0/CB5wIBTZvoL4f4lGlgiJznd6kQqeAePqdTYzTn66446mqQHYZE8w20wLAyDV4K55/5jimyl9b230= on 11/06/2023

Skin malignancies are the most prevalent cancers, and plastic surgeons are often the primary physicians engaged in diagnosis and management of these lesions.[1] Basal cell carcinoma is the most commonly seen skin malignancy, followed by squamous cell carcinoma. The estimated annual incidence of skin cancer is over 3.5 million in the United States alone.[2] In recent years, treatment for these entities has improved, because of new therapeutic options for basal cell carcinoma and a new staging system for squamous cell carcinoma. Identification of high-risk lesions is of utmost importance, especially for squamous cell carcinoma, in which metastatic rates can approach 30 percent when lesions exhibit specific high-risk features.[3]

Appropriate initial treatment of any cutaneous facial malignancy is a key skill for plastic surgeons and should achieve the best cure rates in addition to optimal cosmesis and functional outcomes. Furthermore, treatment should be guided by an accurate diagnosis, confirmed by histologic examination with an adequate biopsy. It is the objective of this Maintenance of Certification article to review the most recent recommendations and practice guidelines and the classification and staging of the most common cutaneous facial malignancies.

From the Dermatology Service and the Plastic Surgery Service, Memorial Sloan Kettering Cancer Center.
Received for publication August 11, 2015; accepted October 26, 2015.
Copyright © 2016 by the American Society of Plastic Surgeons
DOI: 10.1097/PRS.0000000000002853

BASAL CELL CARCINOMA

Background and Diagnosis

As the most common malignancy, basal cell carcinoma accounts for an estimated 1.2 million cases per year in the United States.[1] Overall, white individuals have a one in five chance of developing at least one basal cell carcinoma in their lifetime.[4] Facial location is the most common for this neoplasm, with approximately 80 percent of lesions occurring on the head and neck,[5] because of this location's maximal exposure to ultraviolet radiation. Overall, the nose is the most frequent location affected by basal cell carcinoma.[6] Light skin and eye color, red or blond hair, and propensity to developing sunburn all predispose

Disclosure: *The authors have no relevant financial disclosures or commercial associations to report.*

Supplemental digital content is available for this article. Direct URL citations appear in the text; simply type the URL address into any Web browser to access this content. Clickable links to the material are provided in the HTML text of this article on the *Journal*'s website (www.PRSJournal.com).

Copyright © 2016 American Society of Plastic Surgeons. Unauthorized reproduction of this article is prohibited.

Downloaded from http://journals.lww.com/plasreconsurg by RzUSysRlyqiZg+J5ivYjoyV6s6t/G+nVOYytTyC2t5u bv2Mw44Nk6awDKbkjm0/CB5wIBTZvoL4f4lGIgiJznd6kQqeAePqdTYzTn66446mqQHYZE8w20wLAyDV4K55/5jimyl9b230= on 11/06/2023

to development of basal cell carcinoma.[7] Other risk factors include history of ionizing radiation (risk is increased within the radiation field)[8,9] and ingestion of arsenic.[5,10] Mutations in the tumor suppressor gene Patched or activating mutations in Smoothened, both of which result in up-regulated Hedgehog pathway signaling, are seen in the majority of basal cell carcinomas. In addition, 40 to 65 percent of sporadic basal cell carcinomas demonstrate mutations in the tumor suppressor p53, many with ultraviolet signature mutations.[11] The geographic prevalence of basal cell carcinoma varies widely based on ultraviolet exposure, and Australia has the highest incidence in the world.[12] Rates in the population younger than 40 years has been increasing, particularly in young women.[13]

The natural history of basal cell carcinoma is that of a slow-growing, indolent neoplasm, which is locally destructive but rarely metastasizes. Clinically, the appearance of basal cell carcinoma can be quite varied, depending on tumor subtype. Nodular basal cell carcinoma tends to present as a pink, shiny to pearly papule, often with prominent overlying telangiectasias. Lesions tend to be friable, and can present as isolated nonhealing erosions. The classic "rodent ulcer" refers to the clinical variant with a central ulceration and peripheral border. Pigmented variants of nodular basal cell carcinoma can have a gray to blue color and can be mistaken for a nodular melanoma. Superficial basal cell carcinoma can present as a scaly pink patch and is often confused with papulosquamous entities. Morpheaform basal cell carcinoma can appear similar to a scar with a subtle clinical appearance, making diagnosis more challenging (Fig. 1).

Diagnosis is made by biopsy and histopathologic examination, with a shave or punch biopsy technique commonly used. Histopathologic subtypes of basal cell carcinoma include superficial, nodular, infiltrative, morpheaform, and basosquamous, with lesions often demonstrating more than one histopathologic type. Infiltrative, morpheaform, basosquamous (metatypical), sclerosing, or micronodular subtypes are considered higher risk because rates of recurrence are increased in these lesions.[14] Biopsies are often partial and do not sample the entire lesion[15]; Haws et al. showed that 18 percent of basal cell carcinoma biopsy specimens misidentify tumor subtype because

Fig. 1. (*Above*, *left*) Superficial basal cell carcinoma. (*Above*, *right*) Nodular basal cell carcinoma. (*Below*, *left*) Infiltrative basal cell carcinoma. (*Below*, *right*) Pigmented basal cell carcinoma.

Copyright © 2016 American Society of Plastic Surgeons. Unauthorized reproduction of this article is prohibited.

Fig. 2. Mask area of the face. *Shaded areas* indicate an increased risk for skin cancer extension and recurrence.

Downloaded from http://journals.lww.com/plasreconsurg by RzUSysRlyqiZg+J5lvYjoV6s6t/G+nVOYytTyC2t5u bv2Mw44Nk6awDKbkjm0/CB5wIBTZvoL4f4lGlgUJzmd6kQqeAePqdTYzTn66446mqQHYZE8w20wLAyDV4K55/5jlmy9b230= on 11/06/2023

of sampling error, some initially missing a more aggressive histologic subtype.[16]

The H-zone, also called the "mask-area" of the face, represents a higher risk location for skin cancer extension and recurrence (Fig. 2). These areas include the periorbital and eyelid area, perinasal area, lips, preauricular and postauricular areas, temple, ear, mandible, chin, and central face. High-risk features of facial basal cell carcinoma as defined by National Comprehensive Cancer Network criteria include the following: size greater than 6 mm in an H-zone location, size greater than 10 mm in a medium-risk location (i.e., cheeks, forehead, neck), poorly defined borders, a recurrent lesion, immunosuppressed host, presence in a site of previous irradiation, aggressive growth pattern, and presence of perineural involvement.[14]

Video. Supplemental Digital Content 1 demonstrates histologic sectioning for Mohs micrographic surgery. This video is available in the "Related Videos" section of the full-text article on PRSJournal.com or at ***http://links.lww.com/PRS/B913***.

Treatment

Treatment options vary from nonsurgical to surgical treatments, and are chosen based on both tumor- and patient-specific factors. Nonsurgical treatments include topical fluorouracil, topical imiquimod, photodynamic therapy, electrodesiccation and curettage, cryosurgery, and radiation treatment. Surgical treatments are the gold standard and include standard excision and Mohs micrographic surgery. (**See Video, Supplemental Digital Content 1**, which demonstrates histologic sectioning for Mohs micrographic surgery. This video is available in the "Related Videos" section of the full-text article on PRSJournal.com or at ***http://links.lww.com/PRS/B913***.) When selecting a treatment option for a facial basal cell carcinoma, location, tumor size, and histopathologic subtype play roles in decision-making. Lesions at high risk for recurrence, especially those in the H-zone of the face, and those in close proximity to vital structures such as the eyelid, should be given consideration for more definitive treatment with margin control. Mohs micrographic surgery offers a significant advantage in such areas with its tissue-sparing characteristics, possibly simplifying reconstruction. Another consideration is waiting for results of pathologic evaluation and performing a delayed closure in higher risk lesions if Mohs micrographic surgery is not available (Table 1).

Because basal cell carcinoma incidence increases with patient age and lesions are typically

Copyright © 2016 American Society of Plastic Surgeons. Unauthorized reproduction of this article is prohibited.

Table 1. High-Risk Features for Recurrence of Basal Cell Carcinoma

Location	Mask areas of the face (Fig. 2)
Histology	Perineural invasion, morpheaform, micronodular, sclerosing, infiltrative, basosquamous type
Patient factors	Immunosuppression
Clinical factors	Presence in a radiation field, clinically ill-defined lesion

Downloaded from http://journals.lww.com/plasreconsurg by RzUSysRlyqiZg+J5lvYjoV6s6t/G+nVOYyfTyC2t5u bv2Mw44N k6awDKbjm0/CB5wIBTZvoL4f4lGjqJzmd6kQqeAePqdTYzTn66446mqQHYZE8w20wLAyDV4K55/5jjmy9b230= on 11/06/2023

nonfatal, nonsurgical treatment or observation is often discussed for even high-risk lesions in this patient population. National Comprehensive Cancer Network guidelines recommend a 4-mm margin for excision of low-risk basal cell carcinoma, and reexcision, Mohs micrographic surgery, or another technique of complete margin assessment is recommended in the case of a positive surgical margin after initial excision. For primary treatment of high-risk basal cell carcinoma, excision with larger margins and postoperative margin assessment with delayed closure, Mohs micrographic surgery, or radiation (for nonsurgical candidates) are recommended. Consultation with a multidisciplinary tumor board is recommended for very high-risk cases.[14]

Surgical excision involves removal of clinically apparent tumor plus a margin of clinically uninvolved tissue. Histologic examination is then performed by "bread-loaf" sectioning of the tissue, which allows examination of a percentage of the peripheral excision margin.[17] Traditional excision margins of 4 mm are the standard for elliptical excision of basal cell carcinoma, achieving overall 98 percent clearance rates for lesions smaller than 2 cm.[18] However, 4-mm margins are often difficult to achieve for facial lesions close to vital structures, and several studies indicate that larger margins may be needed for certain facial basal cell carcinoma. For example, Schell et al. demonstrated that an 8-mm margin was required to capture 95 percent of high-risk basal cell carcinomas, and a 4.75-mm margin was required to capture 95 percent of low-risk basal cell carcinomas on the face.[19] Kimyai-Asadi et al. showed 20.1 percent positive margins in well-demarcated primary facial basal cell carcinomas excised with less than or equal to 3-mm margins.[20,21] Although it is true that not all of these lesions will grow back, the recurrence rate has been estimated at 26[22] to 27 percent,[23] and recurrent basal cell carcinoma located in a scar is notoriously more complex to treat surgically; therefore, reexcision is advised in the case of positive histologic margins.

For high-risk basal cell carcinomas located on the head and neck larger than 1 cm, located in the H-zone of the face, or of aggressive histologic subtypes, Mohs micrographic surgery has demonstrated lower recurrence rates at 10-year follow-up.[24] Although a randomized controlled trial comparing Mohs micrographic surgery to surgical excision for primary and recurrent basal cell carcinoma of the face showed a nonstatistically significant advantage of Mohs micrographic surgery at 18-month follow-up,[25] longer follow-up at 5 years showed lower recurrence rates in Mohs micrographic surgery compared with primary excision (2.4 percent versus 12.1 percent).[26] Although Mohs micrographic surgery is a limited resource, it should be considered in cases of recurrent basal cell carcinoma and basal cell carcinoma with aggressive histologic subtype, ill-defined borders, and large size.

Fifty-six percent of primary high-risk basal cell carcinomas have been reported to recur more than 5 years postoperatively, emphasizing the need for regular skin examinations and long-term follow-up and monitoring of these patients.[24] Furthermore, the risk of a subsequent primary basal cell carcinoma in the 3 years after a first primary basal cell carcinoma is up to 44 percent.[27] Therefore, current guidelines recommend full skin examination every 6 to 12 months for life.[14]

Nonsurgical Treatment Options

Nonsurgical treatment options for low-risk basal cell carcinoma of the superficial histologic type include topical therapies such as 5-fluorouracil, imiquimod, photodynamic therapy, cryotherapy, laser treatments, and electrodesiccation and curettage. Nonsurgical treatments are sometimes used for higher risk lesions when patients are not appropriate surgical candidates or decline surgical treatment. Radiation therapy has also been used with efficacy in patients who are not surgical candidates in both high- and low-risk lesions.[14]

Until recently, treatment options for metastatic and locally advanced basal cell carcinoma were limited. The development of a selective Hedgehog pathway inhibitor, vismodegib, has become a treatment option for locally advanced and metastatic basal cell carcinoma,[28] which can be helpful in certain advanced facial lesions impinging on vital structures and not amenable to surgery. Vismodegib targets Hedgehog pathway abnormalities by binding and inhibiting

Copyright © 2016 American Society of Plastic Surgeons. Unauthorized reproduction of this article is prohibited.

Downloaded from http://journals.lww.com/plasreconsurg by RzUSysRlyqiZg+J5lvYjoV6s6t/G+nVOYytTyC2l5u bv2Mw44Nk6awDKbkjm0/CB5wIBTZvoL4f4lGjdJzmd6kQqeAePqdTYzTn66446mqQHYZE8w20wLAyDV4K55/5jjmy9b230= on 11/06/2023

Smoothened, normally inhibited by Patched, with a loss of inhibition seen in most basal cell carcinomas. Common side effects include dysgeusia, alopecia, muscle spasms, and weight loss.[29] A multidisciplinary approach to management of advanced basal cell carcinoma can optimize treatment and minimize risk of recurrence.

ACTINIC KERATOSIS AND SQUAMOUS CELL CARCINOMA

Background and Diagnosis

Actinic keratoses present as small, pink, rough macules caused by chronic actinic damage, considered premalignant neoplasms (Fig. 3). An estimated 1 to 10 percent of actinic keratoses transform over time to squamous cell carcinoma[30,31]; therefore, treating these lesions is recommended to prevent the later development of more invasive skin neoplasia. Diagnosis is typically made on a clinical basis. Biopsy, when performed, demonstrates basal keratinocyte atypia including atypical cells and crowding above the basement membrane zone, often with overlying parakeratosis. Mutations in p53 are seen in the majority of actinic keratoses.[32]

Treatments for actinic keratoses include cryotherapy, various topical treatments, and photodynamic therapy with topical photosensitizer application. Lesion-directed treatments refer to treatments for individual or isolated lesions of actinic keratosis. Field treatment refers to treatment of the entire affected area, which targets both individual lesions and the background of actinic damage typically associated with actinic keratoses. Field treatment can consist of topical creams such as 5-fluorouracil, imiquimod, or ingenol mebutate. Photodynamic therapy is an additional option, which involves topical application of a photosensitizer, typically aminolevulinic acid, followed by exposure to a blue or red light source.[33] Threshold for repeated biopsy of actinic keratoses that do not resolve with standard treatment should be low, as occult squamous cell carcinoma may be present within a lesion of actinic keratosis.[34]

Fig. 3. Scalp with extensive actinic damage including actinic keratoses and early squamous cell carcinomas. Field treatment is useful in these clinical scenarios.

SQUAMOUS CELL CARCINOMA

Squamous cell carcinoma accounts for an estimated 700,000 cases annually in the United States.[2] As squamous cell carcinoma represents 20 percent of nonmelanoma skin cancer but the majority of nonmelanoma skin cancer mortality,[35] early and appropriate treatment is essential. Although rare, nodal metastasis occurs in an estimated 3 to 5 percent, with mortality rates estimated at 1.5 to 2.1 percent.[36,37] Significantly related to previous chronic ultraviolet irradiation, pathogenesis is also influenced by underlying immunosuppression and in some cases, such as digital squamous cell carcinoma, is associated with human papillomavirus infection.[38,39] The prevalence of squamous cell carcinoma in the United States corresponds to the level of ultraviolet light exposure, with southern states showing a higher prevalence of squamous cell carcinoma compared with northern states.[12] Although the majority of squamous cell carcinomas are superficial, a subset of lesions with high-risk features carries a risk of deeper invasion, metastasis, and associated mortality, necessitating early and definitive treatment.

Squamous cell carcinoma is staged according to American Joint Committee on Cancer guidelines, which classify high-risk lesions for recurrence, metastasis, and mortality by tumor diameter greater than 2 cm, invasion into cranial bone, anatomical location on the ear or lip, tumor thickness greater than 2 mm or Clark level greater than or equal to IV, poor

Table 2. High-Risk Features for Recurrence and Metastasis of Squamous Cell Carcinoma

Location	Lip or ear, increased incidence of mortality
Tumor diameter	>2 cm
Tumor depth	>2 mm or beyond fat
Perineural invasion	Nerve >0.1 mm
Poor differentiation	
Immunosuppression	

Copyright © 2016 American Society of Plastic Surgeons. Unauthorized reproduction of this article is prohibited.

Downloaded from http://journals.lww.com/plasreconsurg by RzUSysRlyqiZg+J5ivYjoyV6s6t/G+nVOYytTyC2t5u bv2Mw44Nk6awDKbkjm0/CB5wIBTZvoL4f4IGIgiJznd6kQqeAePqdTYzTn66446mqQHYZE8w20wLAyDV4K55/5jimyl9b230= on 11/06/2023

differentiation, and perineural invasion.[40] Other well-known risk factors for more aggressive squamous cell carcinoma behavior include presence in a chronic wound or burn scar and underlying immunosuppression (Table 2).[3,36,41–47] Despite staging criteria, squamous cell carcinoma is not currently required to be reported in tumor registries.

Diagnosis

Clinically, squamous cell carcinoma can appear as a pink, keratotic, indurated macule, papule, or nodule, which can become ulcerated (Fig. 4). Diagnosis is made by shave or incisional biopsy. Histopathologic examination reveals atypical keratinocytes with abundant pink cytoplasm either localized to the epidermis (squamous cell carcinoma in situ/Bowen disease) or invading into the dermis. An examination of the head and neck nodal basins is essential for all patients presenting with squamous cell carcinoma of the face.

Treatment

Surgical treatment with margin assessment is the preferred method for squamous cell carcinoma. Guidelines recommend a minimum 4-mm excision margin to subcutaneous fat for primary low-risk squamous cell carcinoma and 6-mm margin excision for higher risk squamous cell carcinoma to achieve 95 percent clearance rates.[14,48,49] Reexcision is recommended if initial excision shows positive surgical margins. Multidisciplinary management involving a Mohs surgeon may be considered for high-risk lesions for complete margin assessment.[14] Despite these recommendations, Staiano et al. showed that the margins taken by plastic surgeons for squamous cell carcinoma vary, with most surgeons taking a smaller margin around the ear, lip, eyelids, and nose compared with the trunk or limbs.[50]

Fig. 4. Invasive squamous cell carcinoma on the helical rim.

Mohs micrographic surgery is an additional option for treatment of squamous cell carcinoma of the face, with very low recurrence rates of 2.6 and 5.9 percent in primary and recurrent tumors, respectively, at 5-year follow-up.[51] Although Chren et al. performed a prospective cohort study comparing recurrence rates and showed no statistical difference between lesions treated with Mohs micrographic surgery versus excision, the percentage of lesions treated in the H-zone of the face was significantly higher for the Mohs micrographic surgery group, with this group at higher baseline risk for recurrence.[52]

For smaller in situ lesions without other high-risk factors, and for patients who are not surgical candidates, nonsurgical treatment options can be considered and include radiation therapy, cryotherapy, and electrodesiccation and curettage. Topical treatments such as imiquimod, 5-fluorouracil, and photodynamic therapy have been used, although these are not currently preferred treatments.[53]

For very high-risk lesions of squamous cell carcinoma, including those with extensive perineural or large nerve involvement, or those that cannot be cleared surgically, adjuvant radiation therapy and discussion by a multidisciplinary tumor board is recommended by National Comprehensive Cancer Network guidelines.[14] The role of imaging and sentinel lymph node biopsy has not yet been established and is under investigation.

Keratoacanthoma Subtype of Squamous Cell Carcinoma

Keratoacanthoma is a distinct variant of squamous cell carcinoma that displays unique clinical behavior. Lesions typically appear dome-shaped with a crateriform center, often with a more rapid growth than other variants of squamous cell carcinoma, attaining large size over several weeks to months (Fig. 5). Likewise, keratoacanthomas commonly exhibit spontaneous involution; therefore, some groups feel that keratoacanthoma should be classified as a benign growth rather than a true cancer.[54] However, keratoacanthoma has been reported to demonstrate invasion and subsequent

Copyright © 2016 American Society of Plastic Surgeons. Unauthorized reproduction of this article is prohibited.

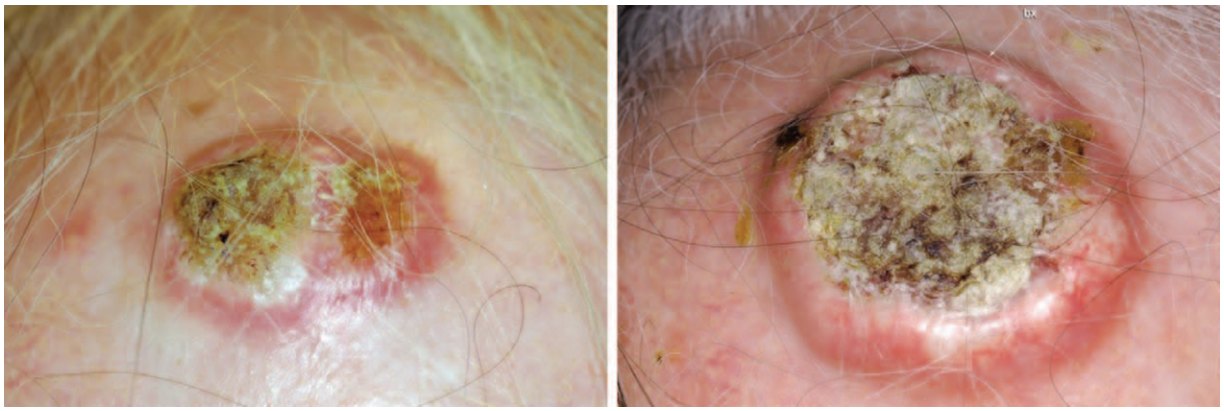

Fig. 5. Keratoacanthoma demonstrating rapid growth over a 3-month period.

Downloaded from http://journals.lww.com/plasreconsurg by RzUSysRlyqiZg+J5lvYjoV6s6t/G+nVOYyfTyC2t5u bv2Mw44Nk6awDKbkjm0/CB5wIBTZvoL4f4lGlgUzmd6kQqeAePqdTYzTn66446mqQHYZE8w20wLAyDV4K55/5jlmy9b230= on 11/06/2023

aggressive behavior, including metastasis.[55] Furthermore, significant histologic overlap in classic squamous cell carcinoma and keratoacanthoma exists, making prediction of clinical behavior sometimes difficult based on clinical and histologic grounds.[56] Histologic evidence of perineural invasion is seen in 2.5 to 14 percent of cases occurring on the head and neck, with unclear prognostic importance.[57]

UNCOMMON FACIAL MALIGNANCIES

Merkel Cell Carcinoma

Merkel cell carcinoma, also known as neuroendocrine carcinoma of the skin, is a rare cutaneous malignancy with aggressive behavior and higher mortality rates than cutaneous melanoma. Risk factors include chronic ultraviolet radiation, immunosuppression, and possibly Merkel cell polyomavirus infection.[58–60] Clinically, Merkel cell carcinoma typically presents as an asymptomatic, erythematous, rapidly growing papule or nodule, most frequently located on the head and neck.[61,62] Staging is performed using American Joint Committee on Cancer (7th edition) guidelines for Merkel cell carcinoma, as follows: stage I, primary tumor size less than 2 cm; stage II, primary tumor size greater than 2 cm; stage III, any nodal disease; and stage IV, distant metastatic disease.[63] Given the very high risk of metastasis in Merkel cell carcinoma, in the absence of palpable lymphadenopathy, sentinel lymph node biopsy is recommended routinely, with a risk of positive biopsy in approximately 30 percent of patients.[62] Surgical treatment is by wide local excision of the primary lesion, using 1- to 2-cm margins to fascia or pericranium; when feasible, the goal is to achieve histologically clear margins. In cases where tissue sparing is of utmost importance, Mohs micrographic surgery may be used. Postsurgical adjuvant radiation may be considered, and may decrease the risk of recurrence.[64] Consultation with a multidisciplinary tumor board is recommended for patients with metastatic disease.[58]

Atypical Fibroxanthoma

Atypical fibroxanthoma is an uncommon fibrohistiocytic tumor typically presenting as an erythematous friable papule or nodule in sun-exposed areas on the head and neck of the elderly population (Fig. 6). Pathogenesis is thought to be related to ultraviolet exposure.[11] Biopsy is used to establish the diagnosis, and reveals atypical spindle cells, necessitating use of immunostains to differentiate atypical fibroxanthoma from other malignancies such as squamous cell carcinoma or melanoma. Malignant fibrous histiocytoma represents a deeper, more aggressive tumor that can be histologically identical to atypical fibroxanthoma but shows deeper invasion. Atypical fibroxanthoma is typically treated surgically, with wide

Fig. 6. Atypical fibroxanthoma on the helical rim. These lesions typically present in sun-damaged skin of the elderly.

Copyright © 2016 American Society of Plastic Surgeons. Unauthorized reproduction of this article is prohibited.

Downloaded from http://journals.lww.com/plasreconsurg by RzUSysRlyqiZg+J5lvYjoV6s6t/G+nVOYytTyC2t5u bv2Mw44Nk6awDKbkjm0/CB5wIBTZvoL4f4lGlgUzmd6kQqeAePqdTYzTn66446mqQHYZE8w20wLAyDV4K55/5jlmy9b230= on 11/06/2023

Fig. 7. Sebaceous carcinoma. The orange/yellow hue is characteristic of these lesions.

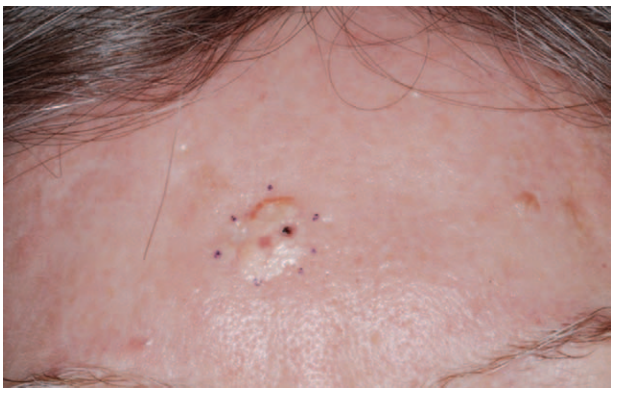

Fig. 8. Microcystic adnexal carcinoma demonstrating the typical sclerotic appearance.

local excision with 1- to 2-cm margins to fascia, or Mohs micrographic surgery. Recurrence rates are reported in approximately 10 percent with wide local excision.[65,66]

Sebaceous Carcinoma

Sebaceous carcinoma is an uncommon malignancy occurring most commonly in the periorbital area. Clinically, lesions are often yellow-pink papules and can resemble more commonly seen neoplasms such as basal cell carcinoma or sebaceous hyperplasia (Fig. 7). Histopathology confirms the diagnosis with collections of dermal sebaceous cells. Any patient diagnosed with a sebaceous neoplasm must be screened for Muir-Torre syndrome, a hereditary syndrome with a defect in DNA mismatch repair predisposing to sebaceous neoplasms and colorectal and genitourinary cancers. Muir-Torre syndrome is inherited in an autosomal dominant manner or can be the result of spontaneous mutation.[67,68] Treatment with Mohs micrographic surgery is commonly performed for sebaceous carcinoma, given the close proximity to the eyelids/periorbital area. For extraocular sebaceous carcinoma, wide local excision can be performed. Regional lymph node metastasis has been reported in lesions with more aggressive clinical and histologic features such as poor differentiation, but reported rates are low, estimated at 2.4 percent.[65,69,70]

Microcystic Adnexal Carcinoma

Microcystic adnexal carcinoma is a rare cutaneous neoplasm most commonly seen on the head and neck. Lesions can appear clinically subtle and often resembles a scar or subtle indurated papule or plaque (Fig. 8). Histopathology is distinctive, with small "tadpole-shaped" basaloid cells occasionally recapitulating ducts. Microcystic adnexal carcinomas tend to be locally recurrent and show subclinical extension with infiltrative growth. In a small case series of 48 patients, 47 percent of 30 lesions treated with simple excision had positive margins. Given the propensity for extensive subclinical growth, Mohs micrographic surgery has been used with success in treating this entity.[65,71]

The prevalence of nonmelanoma skin cancers and their frequent presentation to the plastic surgeon necessitate familiarity and expertise in dealing with these entities. Knowledge of risk factors for higher risk subtypes is essential when determining appropriate management of these common malignancies. Interdisciplinary management and a team approach for more difficult lesions can optimize care.

Joseph J. Disa, M.D.
Plastic Surgery Service
Memorial Sloan Kettering Cancer Center
1275 York Avenue
New York, N.Y. 10065
disaj@mskcc.org

REFERENCES

1. Miller DL, Weinstock MA. Nonmelanoma skin cancer in the United States: Incidence. *J Am Acad Dermatol.* 1994;30:774–778.
2. Rogers HW, Weinstock MA, Harris AR, et al. Incidence estimate of nonmelanoma skin cancer in the United States, 2006. *Arch Dermatol.* 2010;146:283–287.
3. Rowe DE, Carroll RJ, Day CL Jr. Prognostic factors for local recurrence, metastasis, and survival rates in squamous cell carcinoma of the skin, ear, and lip: Implications for treatment modality selection. *J Am Acad Dermatol.* 1992;26:976–990.
4. Stern RS. Prevalence of a history of skin cancer in 2007: Results of an incidence-based model. *Arch Dermatol.* 2010;146:279–282.

Copyright © 2016 American Society of Plastic Surgeons. Unauthorized reproduction of this article is prohibited.

Downloaded from http://journals.lww.com/plasreconsurg by RzUSysRtyqiZg+J5lvYjoV6s6t/G+nVOYyfTyC2t5u bv2Mw44Nk6awDKbkjm0/CB5wIBTZvoL4f4lGjdJzmd6kQqeAePqdTYzTn66446mqQHYZE8w20wLAyDV4K55/5jjmy9b230= on 11/06/2023

5. Wong CS, Strange RC, Lear JT. Basal cell carcinoma. *BMJ* 2003;327:794–798.
6. Choi JH, Kim YJ, Kim H, Nam SH, Choi YW. Distribution of basal cell carcinoma and squamous cell carcinoma by facial esthetic unit. *Arch Plast Surg.* 2013;40:387–391.
7. Kyrgidis A, Tzellos TG, Vahtsevanos K, Triaridis S. New concepts for basal cell carcinoma: Demographic, clinical, histological risk factors, and biomarkers. A systematic review of evidence regarding risk for tumor development, susceptibility for second primary and recurrence. *J Surg Res.* 2010;159:545–556.
8. Lichter MD, Karagas MR, Mott LA, Spencer SK, Stukel TA, Greenberg ER. Therapeutic ionizing radiation and the incidence of basal cell carcinoma and squamous cell carcinoma. The New Hampshire Skin Cancer Study Group. *Arch Dermatol.* 2000;136:1007–1011.
9. Karagas MR, Nelson HH, Zens MS, et al. Squamous cell and basal cell carcinoma of the skin in relation to radiation therapy and potential modification of risk by sun exposure. *Epidemiology* 2007;18:776–784.
10. Netscher DT, Leong M, Orengo I, Yang D, Berg C, Krishnan B. Cutaneous malignancies: Melanoma and nonmelanoma types. *Plast Reconstr Surg.* 2011;127:37e–56e.
11. Kraft S, Granter SR. Molecular pathology of skin neoplasms of the head and neck. *Arch Pathol Lab Med.* 2014;138:759–787.
12. Lomas A, Leonardi-Bee J, Bath-Hextall F. A systematic review of worldwide incidence of nonmelanoma skin cancer. *Br J Dermatol.* 2012;166:1069–1080.
13. Christenson LJ, Borrowman TA, Vachon CM, et al. Incidence of basal cell and squamous cell carcinomas in a population younger than 40 years. *JAMA* 2005;294:681–690.
14. Miller SJ, Alam M, Andersen J, et al. Basal cell and squamous cell skin cancers. *J Natl Compr Canc Netw.* 2010;8:836–864.
15. Rogers CR, Bentz ML. An evidence-based approach to the treatment of nonmelanoma facial skin malignancies. *Plast Reconstr Surg.* 2011;127:940–948.
16. Haws AL, Rojano R, Tahan SR, Phung TL. Accuracy of biopsy sampling for subtyping basal cell carcinoma. *J Am Acad Dermatol.* 2012;66:106–111.
17. Abide JM, Nahai F, Bennett RG. The meaning of surgical margins. *Plast Reconstr Surg.* 1984;73:492–497.
18. Wolf DJ, Zitelli JA. Surgical margins for basal cell carcinoma. *Arch Dermatol.* 1987;123:340–344.
19. Schell AE, Russell MA, Park SS. Suggested excisional margins for cutaneous malignant lesions based on Mohs micrographic surgery. *JAMA Facial Plast Surg.* 2013;15:337–343.
20. Kimyai-Asadi A, Alam M, Goldberg LH, Peterson SR, Silapunt S, Jih MH. Efficacy of narrow-margin excision of well-demarcated primary facial basal cell carcinomas. *J Am Acad Dermatol.* 2005;53:464–468.
21. Ghosh S, Duvvi S, Goodyear P, Reddy E, Kumar A. Evaluation of surgeons' marking of excision margins for superficial facial skin cancer lesions. *J Laryngol Otol.* 2009;123:195–198.
22. Bozan A, Gode S, Kaya I, et al. Long-term follow-up of positive surgical margins in basal cell carcinoma of the face. *Dermatol Surg.* 2015;41:761–767.
23. Gulleth Y, Goldberg N, Silverman RP, Gastman BR. What is the best surgical margin for a basal cell carcinoma: A meta-analysis of the literature. *Plast Reconstr Surg.* 2010;126:1222–1231.
24. van Loo E, Mosterd K, Krekels GA, et al. Surgical excision versus Mohs' micrographic surgery for basal cell carcinoma of the face: A randomised clinical trial with 10 year follow-up. *Eur J Cancer* 2014;50:3011–3020.
25. Smeets NW, Krekels GA, Ostertag JU, et al. Surgical excision vs Mohs' micrographic surgery for basal-cell carcinoma of the face: Randomised controlled trial. *Lancet* 2004;364:1766–1772.
26. Mosterd K, Krekels GA, Nieman FH, et al. Surgical excision versus Mohs' micrographic surgery for primary and recurrent basal-cell carcinoma of the face: A prospective randomised controlled trial with 5-years' follow-up. *Lancet Oncol.* 2008;9:1149–1156.
27. Marcil I, Stern RS. Risk of developing a subsequent nonmelanoma skin cancer in patients with a history of nonmelanoma skin cancer: A critical review of the literature and meta-analysis. *Arch Dermatol.* 2000;136:1524–1530.
28. Von Hoff DD, LoRusso PM, Rudin CM, et al. Inhibition of the hedgehog pathway in advanced basal-cell carcinoma. *N Engl J Med.* 2009;361:1164–1172.
29. Harms KL, Dlugosz AA. Harnessing hedgehog for the treatment of basal cell carcinoma. *JAMA Dermatol.* 2013;149:607–608.
30. Marks R, Foley P, Goodman G, Hage BH, Selwood TS. Spontaneous remission of solar keratoses: The case for conservative management. *Br J Dermatol.* 1986;115:649–655.
31. Dodson JM, DeSpain J, Hewett JE, Clark DP. Malignant potential of actinic keratoses and the controversy over treatment: A patient-oriented perspective. *Arch Dermatol.* 1991;127:1029–1031.
32. Ortonne JP. From actinic keratosis to squamous cell carcinoma. *Br J Dermatol.* 2002;146(Suppl 61):20–23.
33. Gupta AK, Paquet M, Villanueva E, Brintnell W. Interventions for actinic keratoses. *Cochrane Database Syst Rev.* 2012;12:CD004415.
34. Iorio ML, Ter Louw RP, Kauffman CL, Davison SP. Evidence-based medicine: Facial skin malignancy. *Plast Reconstr Surg.* 2013;132:1631–1643.
35. Girschik J, Fritschi L, Threlfall T, Slevin T. Deaths from nonmelanoma skin cancer in Western Australia. *Cancer Causes Control* 2008;19:879–885.
36. Brantsch KD, Meisner C, Schönfisch B, et al. Analysis of risk factors determining prognosis of cutaneous squamous-cell carcinoma: A prospective study. *Lancet Oncol.* 2008;9:713–720.
37. Karia PS, Han J, Schmults CD. Cutaneous squamous cell carcinoma: Estimated incidence of disease, nodal metastasis, and deaths from disease in the United States, 2012. *J Am Acad Dermatol.* 2013;68:957–966.
38. Alam M, Caldwell JB, Eliezri YD. Human papillomavirus-associated digital squamous cell carcinoma: Literature review and report of 21 new cases. *J Am Acad Dermatol.* 2003;48:385–393.
39. Riddel C, Rashid R, Thomas V. Ungual and periungual human papillomavirus-associated squamous cell carcinoma: A review. *J Am Acad Dermatol.* 2011;64:1147–1153.
40. Edge SB, Byrd DR, Compton CC. Cutaneous squamous cell carcinoma and other cutaneous carcinomas. In: Edge SE , Byrd DG , Compton CC , Fritz AG , Greene FL , Trotti A, eds. *AJCC Cancer Staging Manual.* 7th ed. New York: Springer Verlag; 2010:301–314.
41. Mehrany K, Weenig RH, Lee KK, Pittelkow MR, Otley CC. Increased metastasis and mortality from cutaneous squamous cell carcinoma in patients with chronic lymphocytic leukemia. *J Am Acad Dermatol.* 2005;53:1067–1071.
42. Schmults CD, Karia PS, Carter JB, Han J, Qureshi AA. Factors predictive of recurrence and death from cutaneous squamous cell carcinoma: A 10-year, single-institution cohort study. *JAMA Dermatol.* 2013;149:541–547.
43. Roozeboom MH, Lohman BG, Westers-Attema A, et al. Clinical and histological prognostic factors for local recurrence and metastasis of cutaneous squamous cell

Copyright © 2016 American Society of Plastic Surgeons. Unauthorized reproduction of this article is prohibited.

carcinoma: Analysis of a defined population. *Acta Derm Venereol.* 2013;93:417–421.
44. Brougham ND, Dennett ER, Cameron R, Tan ST. The incidence of metastasis from cutaneous squamous cell carcinoma and the impact of its risk factors. *J Surg Oncol.* 2012;106:811–815.
45. Jambusaria-Pahlajani A, Kanetsky PA, Karia PS, et al. Evaluation of AJCC tumor staging for cutaneous squamous cell carcinoma and a proposed alternative tumor staging system. *JAMA Dermatol.* 2013;149:402–410.
46. Kyrgidis A, Tzellos TG, Kechagias N, et al. Cutaneous squamous cell carcinoma (SCC) of the head and neck: Risk factors of overall and recurrence-free survival. *Eur J Cancer* 2010;46:1563–1572.
47. Clayman GL, Lee JJ, Holsinger FC, et al. Mortality risk from squamous cell skin cancer. *J Clin Oncol.* 2005;23:759–765.
48. Brodland DG, Zitelli JA. Surgical margins for excision of primary cutaneous squamous cell carcinoma. *J Am Acad Dermatol.* 1992;27:241–248.
49. Motley R, Kersey P, Lawrence C; British Association of Dermatologists; British Association of Plastic Surgeons. Multiprofessional guidelines for the management of the patient with primary cutaneous squamous cell carcinoma. *Br J Plast Surg.* 2003;56:85–91.
50. Staiano JJ, Juma A, Dhital SK, McGeorge DD. Excision margin for cutaneous squamous cell carcinoma: Is it standardised? *Eur J Plast Surg.* 2004;27:135–139.
51. Leibovitch I, Huilgol SC, Selva D, Hill D, Richards S, Paver R. Cutaneous squamous cell carcinoma treated with Mohs micrographic surgery in Australia: II. Perineural invasion. *J Am Acad Dermatol.* 2005;53:261–266.
52. Chren MM, Torres JS, Stuart SE, Bertenthal D, Labrador RJ, Boscardin WJ. Recurrence after treatment of nonmelanoma skin cancer: A prospective cohort study. *Arch Dermatol.* 2011;147:540–546.
53. Bath-Hextall FJ, Matin RN, Wilkinson D, Leonardi-Bee J. Interventions for cutaneous Bowen's disease. *Cochrane Database Syst Rev.* 2013;6:CD007281.
54. Savage JA, Maize JC Sr. Keratoacanthoma clinical behavior: A systematic review. *Am J Dermatopathol.* 2014;36:422–429.
55. Hodak E, Jones RE, Ackerman AB. Solitary keratoacanthoma is a squamous-cell carcinoma: Three examples with metastases. *Am J Dermatopathol.* 1993;15:332–342; discussion 343.
56. Cribier B, Asch P, Grosshans E. Differentiating squamous cell carcinoma from keratoacanthoma using histopathological criteria: Is it possible? A study of 296 cases. *Dermatology* 1999;199:208–212.
57. Petrie M, Eliezri Y, Campanelli C. Keratoacanthoma of the head and neck with perineural invasion: Incidental finding or cause for concern? *Dermatol Surg.* 2010;36:1209–1213.
58. Bichakjian CK, Olencki T, Alam M, et al. Merkel cell carcinoma, version 1.2014. *J Natl Compr Canc Netw.* 2014;12:410–424.
59. Santos-Juanes J, Fernández-Vega I, Fuentes N, et al. Merkel cell carcinoma and Merkel cell polyomavirus: A systematic review and meta-analysis. *Br J Dermatol.* 2015;173:42–49.
60. Saini AT, Miles BA. Merkel cell carcinoma of the head and neck: Pathogenesis, current and emerging treatment options. *Onco Targets Ther.* 2015;8:2157–2167.
61. Heath M, Jaimes N, Lemos B, et al. Clinical characteristics of Merkel cell carcinoma at diagnosis in 195 patients: The AEIOU features. *J Am Acad Dermatol.* 2008;58:375–381.
62. Smith FO, Yue B, Marzban SS, et al. Both tumor depth and diameter are predictive of sentinel lymph node status and survival in Merkel cell carcinoma. *Cancer* 2015;121:3252–3260.
63. Edge SB; American Joint Committee on Cancer; American Cancer Society. *AJCC Cancer Staging Handbook: From the AJCC Cancer Staging Manual.* 7th ed. New York: Springer; 2010.
64. Lewis KG, Weinstock MA, Weaver AL, Otley CC. Adjuvant local irradiation for Merkel cell carcinoma. *Arch Dermatol.* 2006;142:693–700.
65. Reinstadler DR, Sinha UK. Uncommon cutaneous neoplasms of the head and neck. *Facial Plast Surg Clin North Am.* 2012;20:483–491.
66. Davis JL, Randle HW, Zalla MJ, Roenigk RK, Brodland DG. A comparison of Mohs micrographic surgery and wide excision for the treatment of atypical fibroxanthoma. *Dermatol Surg.* 1997;23:105–110.
67. Kyllo RL, Brady KL, Hurst EA. Sebaceous carcinoma: Review of the literature. *Dermatol Surg.* 2015;41:1–15.
68. Ingram JR, Griffiths AP, Roberts DL. All patients with sebaceous gland neoplasms should be screened for Muir-Torre syndrome. *Clin Exp Dermatol.* 2009;34:264–266.
69. Dasgupta T, Wilson LD, Yu JB. A retrospective review of 1349 cases of sebaceous carcinoma. *Cancer* 2009;115:158–165.
70. Tryggvason G, Bayon R, Pagedar NA. Epidemiology of sebaceous carcinoma of the head and neck: Implications for lymph node management. *Head Neck* 2012;34:1765–1768.
71. Chiller K, Passaro D, Scheuller M, Singer M, McCalmont T, Grekin RC. Microcystic adnexal carcinoma: Forty-eight cases, their treatment, and their outcome. *Arch Dermatol.* 2000;136:1355–1359.

Downloaded from http://journals.lww.com/plasreconsurg by RzUSysRtyqiZg+J5ivYjoyV6s6t/G+nVOYytTyC2t5u bv2Mw44Nk6awDKbkjm0/CB5wIBTZvoL4f4lGIgUzmd6kQqeAePqdTYzTn66446mqQHYZE8w20wLAyDV4K55/5jimy9b230= on 11/06/2023

Copyright © 2016 American Society of Plastic Surgeons. Unauthorized reproduction of this article is prohibited.